

Issels Immuno-Oncology

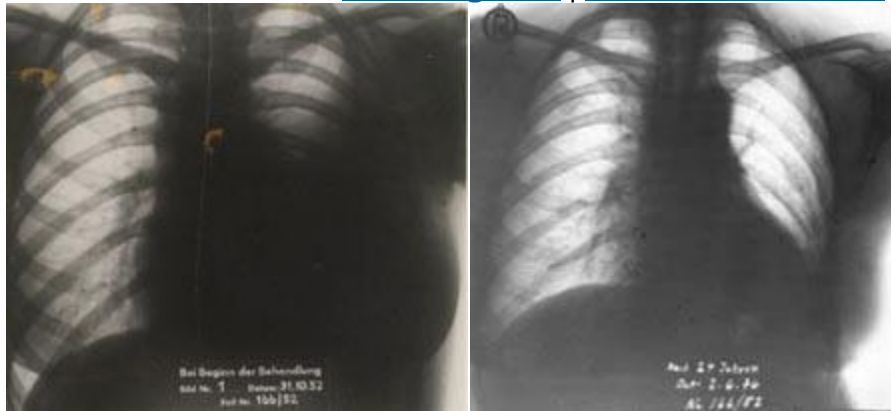
Sarcoma of the Chest Surrounding the Spine and with extensive Lung Involvement

Complete Long Term Remission of a Sarcoma of the Chest Surrounding the Spine and with extensive Lung Involvement through the Immunobiological Issels Treatment without further Standard Treatment

Patient T.C.-D., Born in 1933, file No. 166/52

22 years cancer free without recurrence. Patient got married in 1957, became a mother of 2, leading a normal healthy family life.

TREATMENT HISTORY [First Diagnosis](#) | [Standard Treatment](#) | [Issels Treatment](#)



Beginning of Issels Treatment (1952) and 24 years later (1976), cancer free.

First Diagnosis

1952

Histology, Prof. Dormanns, Solingen: Fibroplastic sarcoma

Standard / Conventional Treatment

September 1952

Partial resection of primary fist size tumor of left chest which surrounded the spinal column. (complete removal impossible)

Issels Immuno-Oncology

October 1952

Radiation of 3000 r.

No remission.

Issels Treatment

October 1952

Admission to Dr. Issels' hospital, (three quarters of the left lung obscured).

14 weeks of Issels Treatment (comprehensive immunotherapy) without chemotherapy.

Partial remission.

September to October 1953

Second admission to Dr. Issels hospital.

4 weeks of intensive Issels Treatment without chemotherapy.

August 1954

Psychic trauma (fiance left her)

First recurrence of the size of two fists. Radiation treatment of 4000 r.

Six weeks after radiation still no remission.

November 1954

Third admission to Dr. Issels' hospital.

Two thirds of the left lung were obscured due to recurrence. Several pea size skin metastases on chest wall.

No further Standard Treatment. Patient considered incurable.

10 weeks of Issels Treatment without chemotherapy.

November 1955

Fourth admission to Dr. Issels hospital for 5 weeks of intensive Issels Treatment.

Inpatient treatment was followed by several months of outpatient treatment.

November to December 1956

Fifth admission for 5 weeks of intensive Issels Treatment.

Issels Immuno-Oncology

Evident regression of lung tumor and of skin metastases.

June 1958

Complete remission.

Observation of 28 years

22 years cancer free without recurrence. Patient got married in 1957, became a mother of 2, leading a normal healthy family life.

DISCLAIMER: No claim is made that patients with similar diagnosis and/or treatment(s) will respond to the same extent as the patients shown. All testimonials have been provided voluntarily to share a patient's experience with the Issels Treatment and their state of health at the time. Some patients may have passed away due to age or disease. None of these patients received compensation or are related to the Issels Treatment Centers.