

Issels Immuno-Oncology

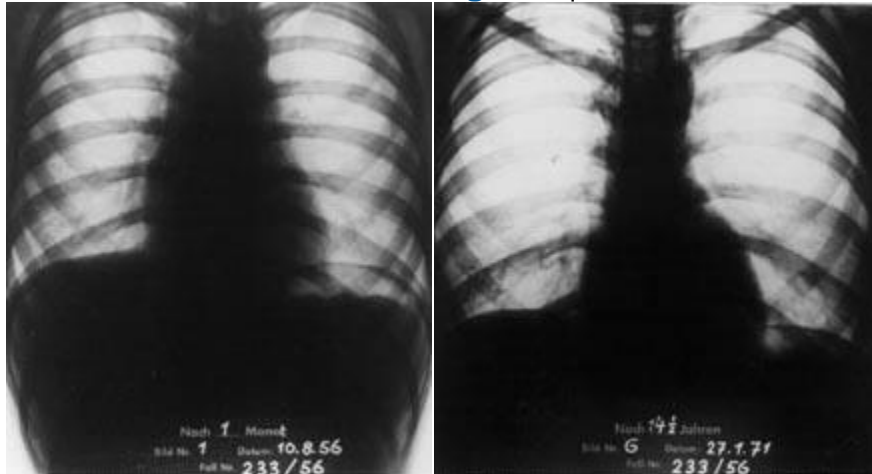
Recurring Non-Hodgkin's Lymphoma with Mediastinal Involvement

Complete Long Term Remission of a Recurring Non-Hodgkin's Lymphoma with Mediastinal Involvement through the Immunobiological Issels Treatment without further Standard Treatment

Patient U.P.- H., Born 1944, file No. 233/56.

39 years cancer free, mother of two healthy children.

TREATMENT HISTORY [First Diagnosis](#) | [Standard Treatment](#) | [Issels Treatment](#)



First Diagnosis

1956

Histology, Bremen: Lymphosarcoma, right neck.

Standard / Conventional Treatment

April 1956

Surgical removal of egg size tumor of right neck.

April/May 1956

Radiation and chemotherapy.

Partial remission.

Issels Immuno-Oncology

July 1956

First recurrence. No Standard Treatment.

Issels Treatment

July 1956

First admission to Dr. Issels' hospital with untreated enlarged mediastinum and induration at the site of primary tumor.

July to October 1956

Ten weeks of Issels Treatment (comprehensive immunotherapy) without chemotherapy. No regression, no progression of disease.

June 1957

Second admission to Dr. Issels' hospital with further spreading of the mediastinum and enlarged lymphnodes of the neck.

June to August 1957

Six weeks of Issels Treatment without chemotherapy. Partial regression.

October 1958

Complete Regression.

Follow-up until 1997

39 years cancer free, mother of two healthy children.

DISCLAIMER: No claim is made that patients with similar diagnosis and/or treatment(s) will respond to the same extent as the patients shown. All testimonials have been provided voluntarily to share a patient's experience with the Issels Treatment and their state of health at the time. Some patients may have passed away due to age or disease. None of these patients received compensation or are related to the Issels Treatment Centers.