

Issels Immuno-Oncology

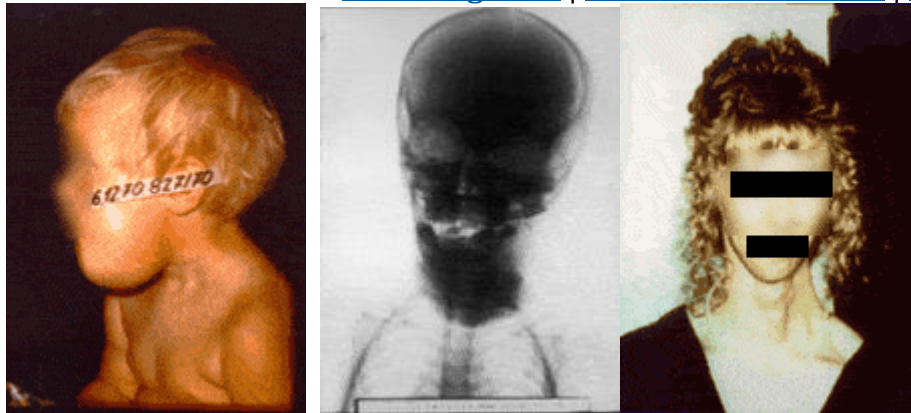
Inoperable Rhabdomyosarcoma Of The Jaw

Inoperable Rhabdomyosarcoma Of The Jaw Rendered Operable Through the Issels Treatment. Subsequent Surgery and Issels Followup Treatment Achieved Longterm Remission.

Patient H.S., Born in 1968, file No. 827/70

30 years cancer free, patient got married, leading a normal healthy life.

TREATMENT HISTORY [First Diagnosis](#) | [Standard Treatment](#) | [Issels Treatment](#)



First Diagnosis

1970, London

Histology, Great Ormond Street Hospital, Rhabdomyosarcoma left jaw.

Standard / Conventional Treatment

May 1970

Treatment : Radiation and Chemotherapy, Great Ormond Street Hospital, London.

The inoperable tumor continued to grow and destroyed jawbone.

Issels Treatment

November 1970

Admission to Dr. Issels hospital.

14 weeks of Issels Treatment (comprehensive immunotherapy).

Issels Immuno-Oncology

Inoperable tumor rendered operable and referred to surgery followed by Issels Treatment

Follow-up until 2002

32 years cancer free, patient got married, leading a normal healthy life.

DISCLAIMER: No claim is made that patients with similar diagnosis and/or treatment(s) will respond to the same extent as the patients shown. All testimonials have been provided voluntarily to share a patient's experience with the Issels Treatment and their state of health at the time. Some patients may have passed away due to age or disease. None of these patients received compensation or are related to the Issels Treatment Centers.