

Issels Immuno-Oncology

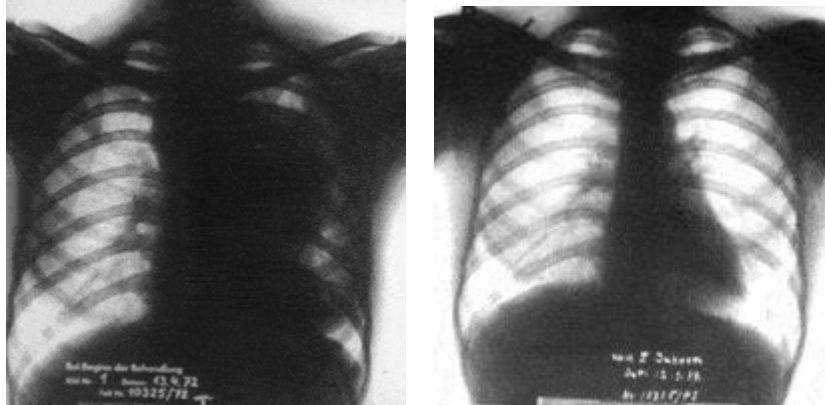
Primary Hodgkin's Lymphoma

Long Term Remission Of Primary Hodgkin's Lymphoma Achieved Through The Issels Treatment With Low Dose Chemotherapy

Patient M.H., Born 1952, file No. 10325/72

26 years cancer free. Patient got married in October 1976 and leads normal life.

TREATMENT HISTORY [First Diagnosis](#) | [Issels Treatment](#)



Beginning of Issels Treatment; then 5 years later, cancer-free.

First Diagnosis

April 1972

Histology, Stuttgart, Nodular sclerosising form of lympho- granulomatosis.(subclavicular left side)

No conventional treatment.

Issels Treatment

April 11, 1972

Admission to Dr. Issels' hospital.

Findings: Subclavicular glandular swelling left side and a tumor of fist size in the left lung.

Issels Immuno-Oncology

April 11 to June 30, 1972

Ten weeks of Issels Treatment (comprehensive immunotherapy) combined with low dose chemotherapy.

Complete remission of subclavicular glands and partial remission of lung tumor. In the following months complete remission of lung tumor. No recurrence.

Follow-up until 1998

26 years cancer free

Patient got married in October 1976 and leads normal life.

DISCLAIMER: No claim is made that patients with similar diagnosis and/or treatment(s) will respond to the same extent as the patients shown. All testimonials have been provided voluntarily to share a patient's experience with the Issels Treatment and their state of health at the time. Some patients may have passed away due to age or disease. None of these patients received compensation or are related to the Issels Treatment Centers.